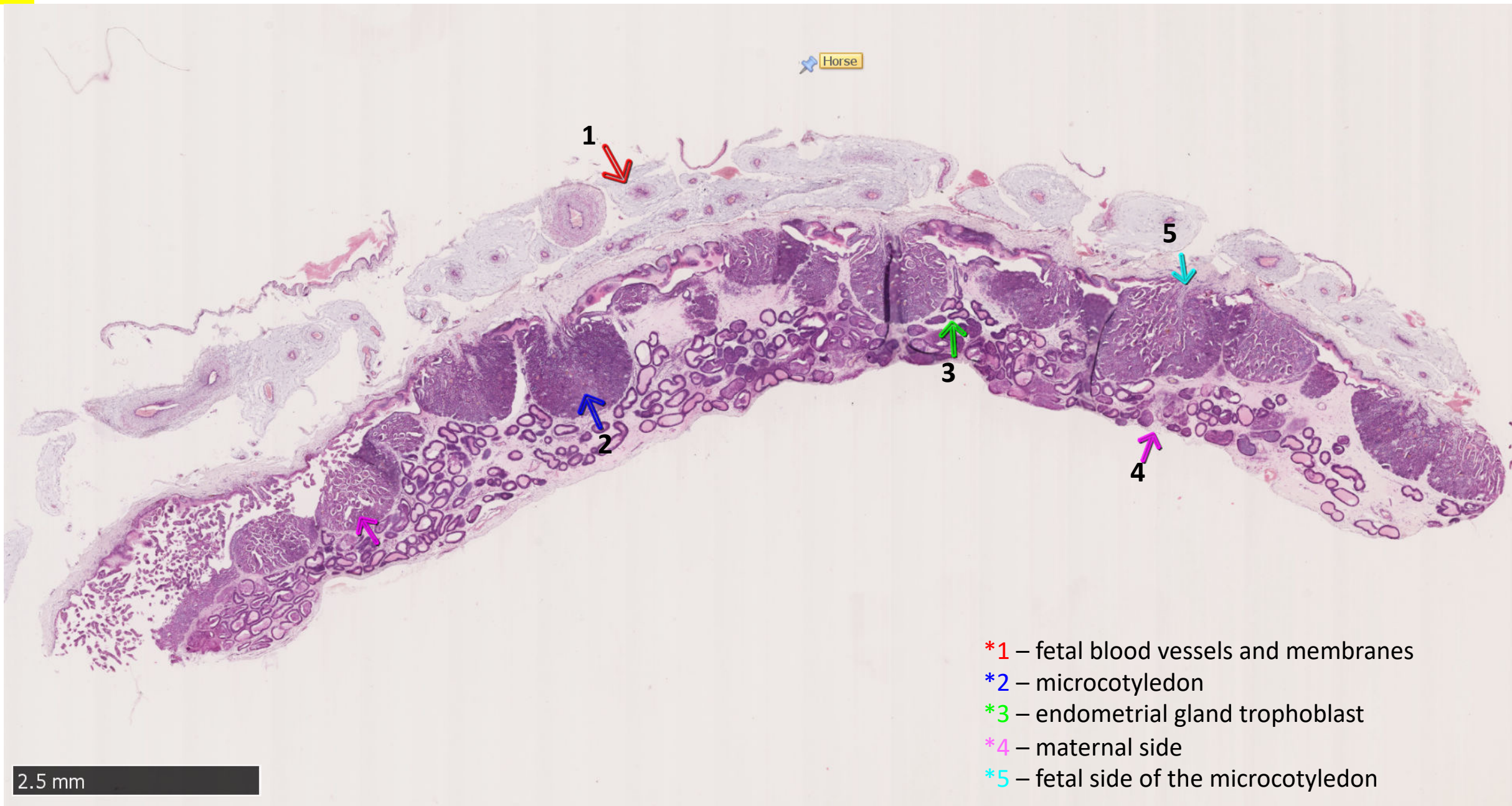


Horse



- *1 – fetal blood vessels and membranes
- *2 – microcotyledon
- *3 – endometrial gland trophoblast
- *4 – maternal side
- *5 – fetal side of the microcotyledon