

H630

Material: Uterus & Placenta

Cr (mm): 30

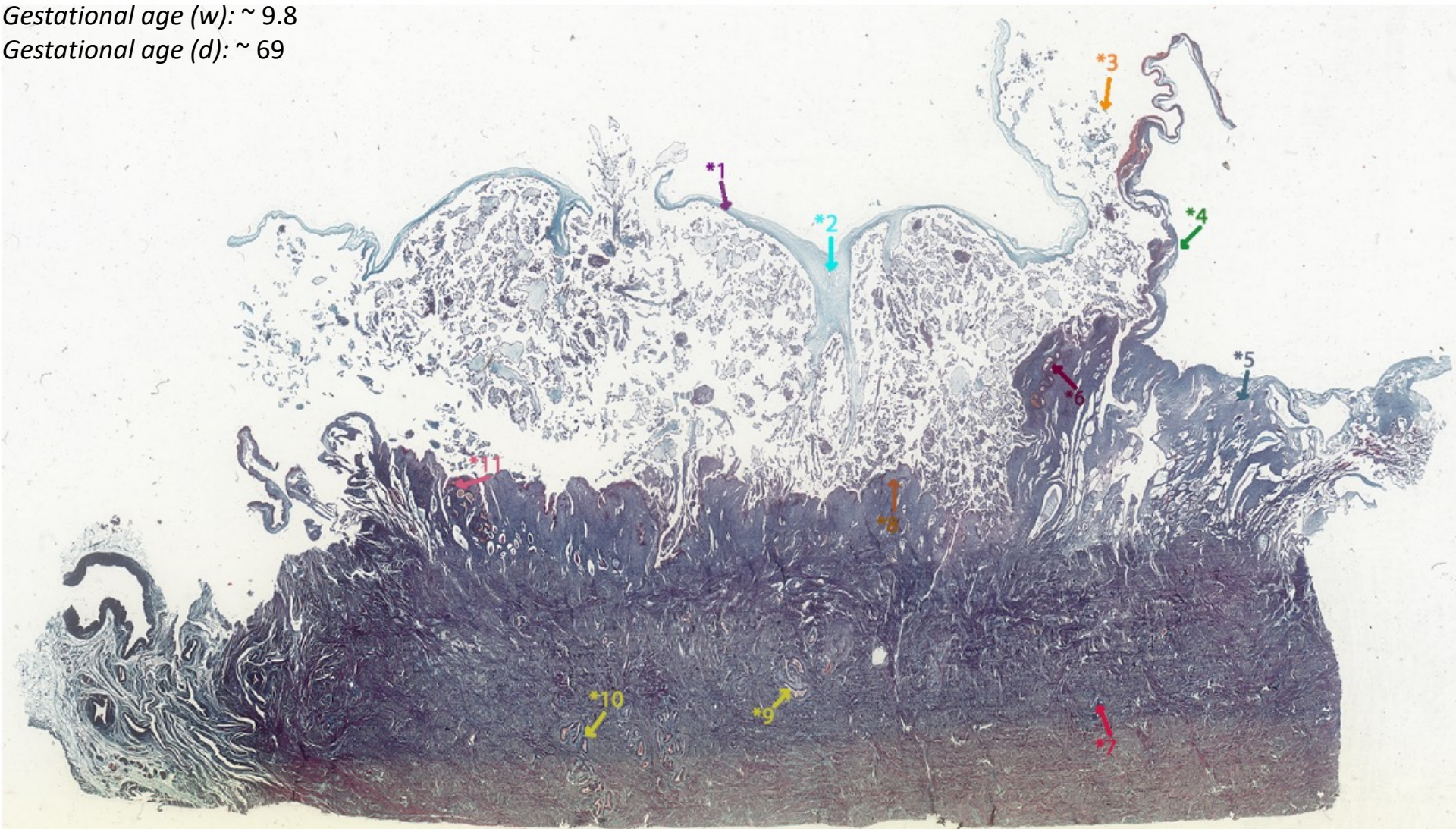
Thickness(μm): 10

Sex: F

Particulars: HYSTERECTOMY (Uterus with
Foetus & Placenta in situ)

Gestational age (w): ~ 9.8

Gestational age (d): ~ 69



- *1 Chorionic plate.
- *2 Stem villus.
- *3 Regressing villi of the chorion laeve.
- *4 Decidua capsularis.
- *5 Decidua parietalis.
- *6 Spiral artery.
- *7 Myometrium.
- *8 Decidua basalis.
Note the uneven thickness at this stage of gestation.
- *9 - *10 Radial arteries.
- *11 Spiral artery undergoing remodeling.