

H630

Material: Uterus & Placenta

Cr (mm): 30

Thickness(μm): 10

Sex: F

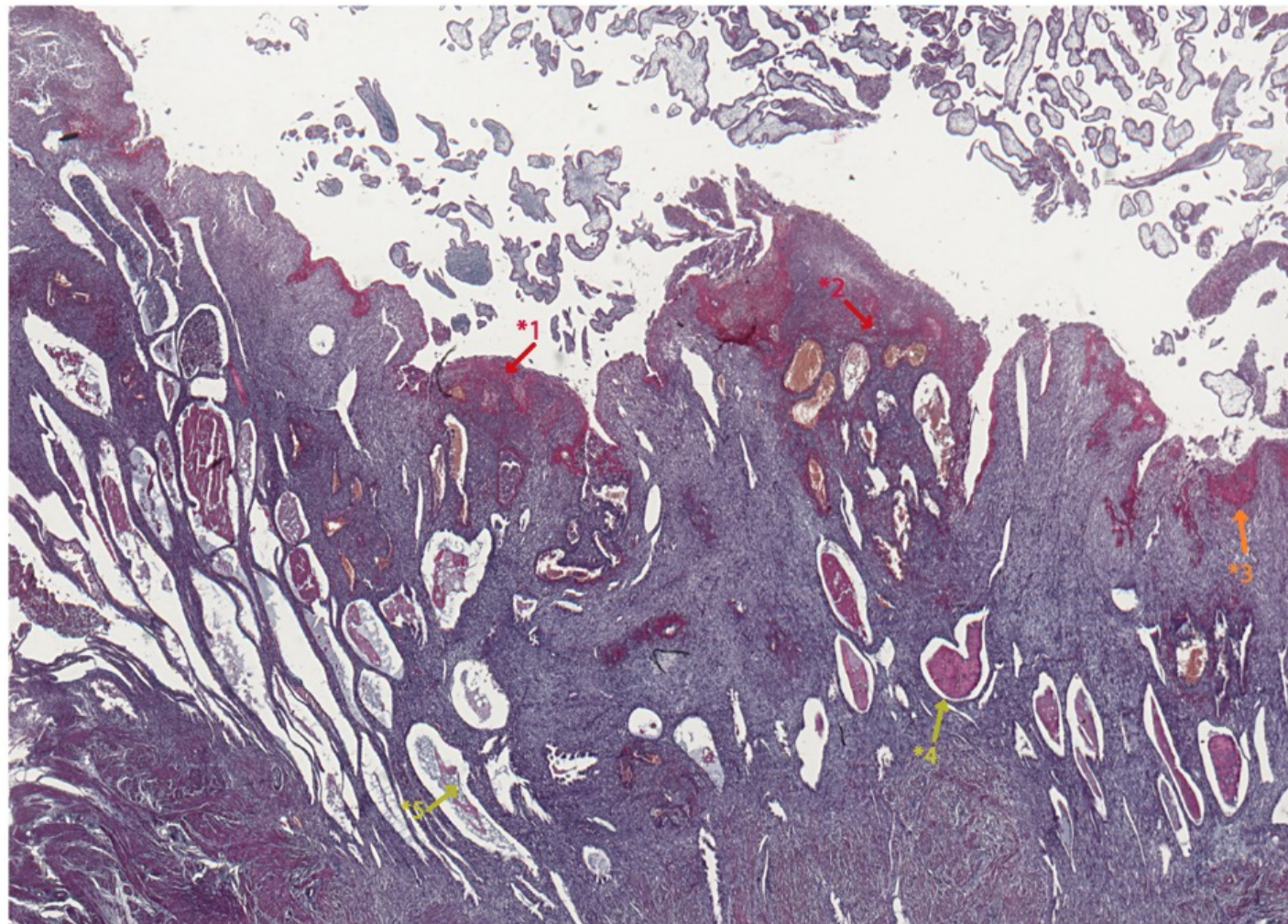
Particulars: HYSTERECTOMY (Uterus with
Foetus & Placenta in situ)

Gestational age (w): ~ 9.8

Gestational age (d): ~ 69



Zoom



- *1 - *2** Terminal segments of a spiral artery undergoing remodelling, as shown by the surrounding deposition of fibrinoid material (staining red).
- *3** Nitabuch's stria of fibrinoid laid down at the maternal-fetal interface.
- *4 - *5** Endometrial (uterine) glands still containing heterogeneous secretions.