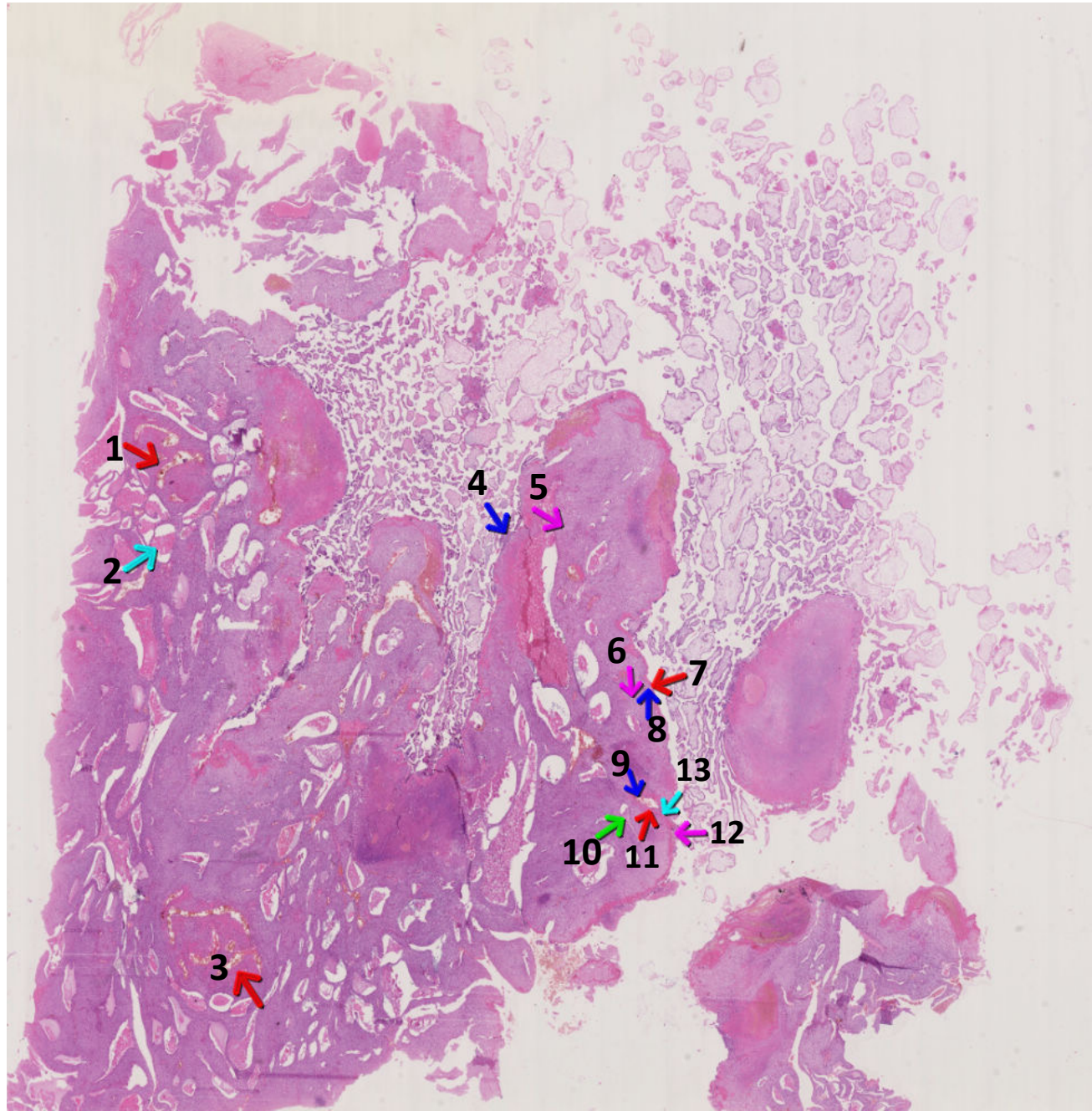


H643

Material: Uterus & Placenta

Gestational age (w): ~ 10

Gestational age (d): ~ 70



- *1 – spiral artery undergoing remode
- *2 – endometrial glands
- *3 – spiral artery undergoing remode
- *4 – anchoring villus
- *5 – decidual cells
- *6 – maternal decidual cells
- *7 – Nitabuch's fibrinoid
- *8 – interstitial trophoblast
- *9 – endovascular trophoblast
- *10 – endometrial gland
- *11 – fibrinoid material
- *12 – cytotrophoblast shell