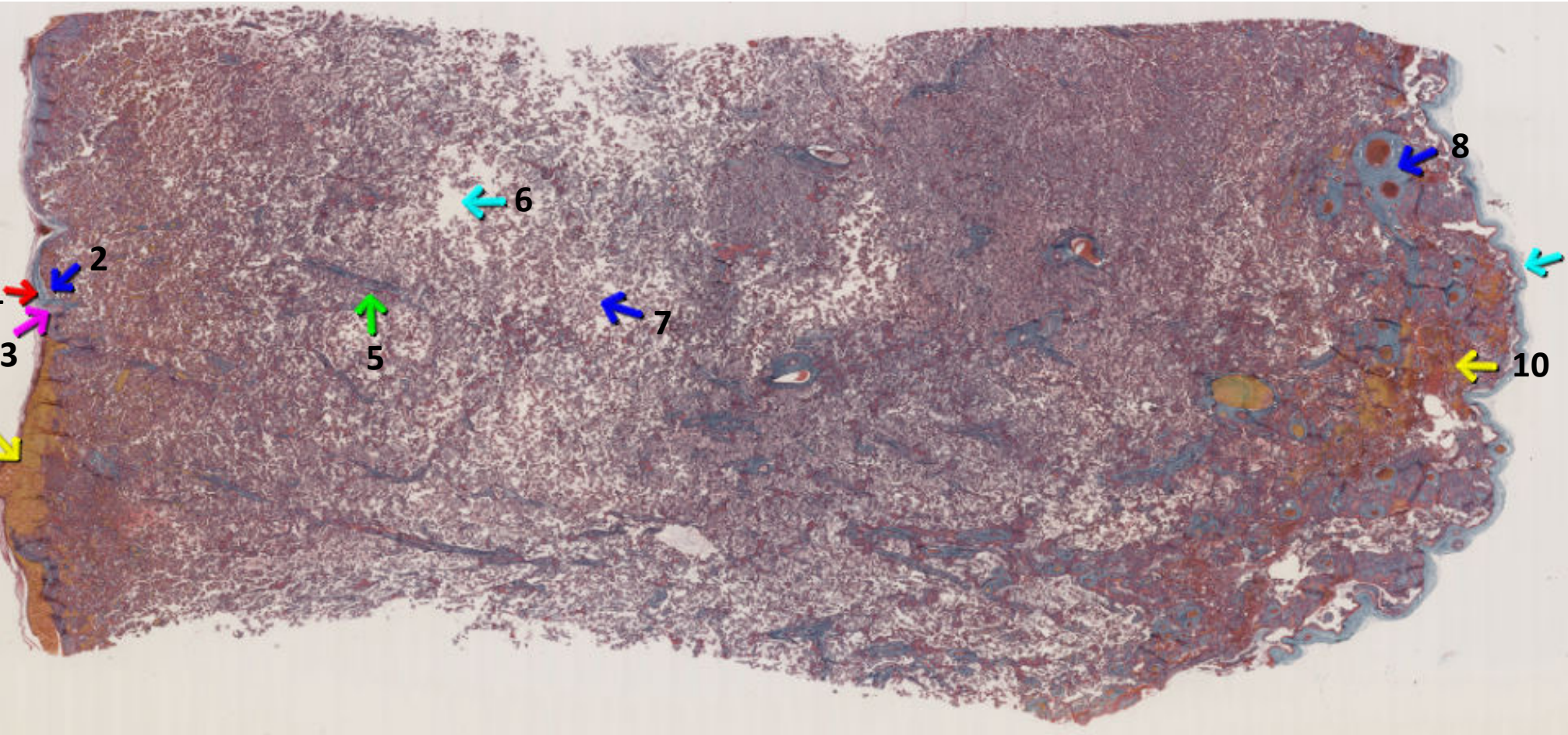


Term human placenta



- *1 – Nitabuch's stria
- *2 – extravillous trophoblasts
- *3 – maternal decidua cells
- *4 – Rohr's stria
- *5 – stem villus
- *6 – intervillous space
- *7 – terminal villi
- *8 – stem villus
- *9 – chorionic plate
- *10 – fibrin deposition